

An Unusual Case of Delayed Hemolytic Transfusion Reaction With Hyperhemolysis Syndrome Due to Anti-Jk^b and Anti-Fy^a Alloantibodies

Kenza El Alaoui^{a, b} , Fleur Samantha Benghiat^a, Martin Colard^a

Abstract

Delayed hemolytic transfusion reaction (DHTR) is a complication appearing a few days to weeks due to alloimmunization following packed red blood cells (RBCs) transfusion, a pregnancy, or transplantation. Hyperhemolysis syndrome (HS) is a severe form of DHTR defined by a drop of hemoglobin to a level lower than before the transfusion, reflecting a destruction of the patient's own RBCs not presenting the targeted antigen as well as the transfused RBCs. Usually seen in sickle cell disease (SCD) patients, HS remains very rare in patients without a hematologic disorder. We report the case of an 82-year-old Caucasian woman who presented with a DHTR with HS after being transfused packed RBC twice in the context of rectal bleeding. The patient was not known for any hemoglobinopathy and did not have a history of massive transfusions nor multiple pregnancies putting her at risk of alloimmunization. Our patient developed anti-C, anti-Fy^a and anti-Jk^b antibodies, known to be harmful antibodies. First line of treatment after avoidance of further transfusions is intravenous immunoglobulins for 3 to 5 days and high-dose corticosteroids. Exceptional in the non-SCD population, this complication should be recalled by clinicians as it can be fatal if not treated appropriately. We performed a review of the literature using the words "delayed hemolytic transfusion reaction" and "hyperhemolysis syndrome" for similar cases. Finally, we describe how to diagnose, manage, and prevent this potentially fatal complication, which is still underrecognized even within the SCD population.

Keywords: Delayed hemolytic transfusion reaction; Hyperhemolysis syndrome; Diagnose; Management

Introduction

Delayed hemolytic transfusion reaction (DHTR) is due to al-

loimmunization following packed red blood cells (RBCs) transfusion, a pregnancy, or transplantation. Due to antibody evanescence with time, further transfusions can induce, in an anamnestic response setting, a hemolytic reaction which appears a few days to weeks (average 9 days) after the transfusion. There is a significant drop of hemoglobin post transfusion, along with an important lactate dehydrogenase (LDH) rise and possible hemoglobinuria. Delayed serologic transfusion reaction, however, refers to the sole identification of an antibody without evidence of hemolysis [1].

DHTR is more common in sickle cell disease (SCD) patients [2, 3], as they are more prone to alloimmunization than other frequently transfused patients. Indeed, usual RBC cross-matching include the main antigens (ABO, RhD), and SCD patients often receive transfusions from blood donors of a different ethnicity, exposing them to different blood group antigens [4].

Hyperhemolysis syndrome (HS) is defined by a drop of hemoglobin to a level lower than before the transfusion, reflecting a destruction of the transfused RBCs with the autologous RBCs [5]. This more severe form of DHTR can lead to life-threatening anemia and end organ damage, requiring immediate management.

Case Report

Investigations

We report the case of an 82-year-old Caucasian woman hospitalized for acute lower gastrointestinal hemorrhage. In her medical history, she was previously diagnosed with hypertension, type 2 diabetes mellitus, hypercholesterolemia and ischemic cardiopathy with a reduced ejection fraction to 40%. Her medication consisted of aspirin, bisoprolol, digoxin, lisinopril, molsidomine, gliclazide and pregabalin. She had two kids and was not known for previous blood transfusions.

In the emergency department, her complete blood count showed normocytic anemia with a hemoglobin level of 7.6 g/dL with a mean corpuscular volume of 95 μm^3 , 267,000 platelets/ mm^3 and 18,800 white blood cells/ mm^3 , predominantly neutrophils. The absolute reticulocyte count was 161,000/ mm^3 with a low reticulocyte production index 1.7. Iron studies were below normal values with a ferritin of 30 $\mu\text{g/L}$ with

Manuscript submitted January 14, 2022, accepted February 22, 2022
Published online April 12, 2022

^aDepartment of Hematology, Erasme Hospital, Universite Libre de Bruxelles, Brussels, Belgium

^bCorresponding Author: Kenza El Alaoui, Department of Hematology, Erasme Hospital, Universite Libre de Bruxelles, Brussels, Belgium.
Email: kenza.el.alaoui@erasme.ulb.ac.be

doi: <https://doi.org/10.14740/jh968>

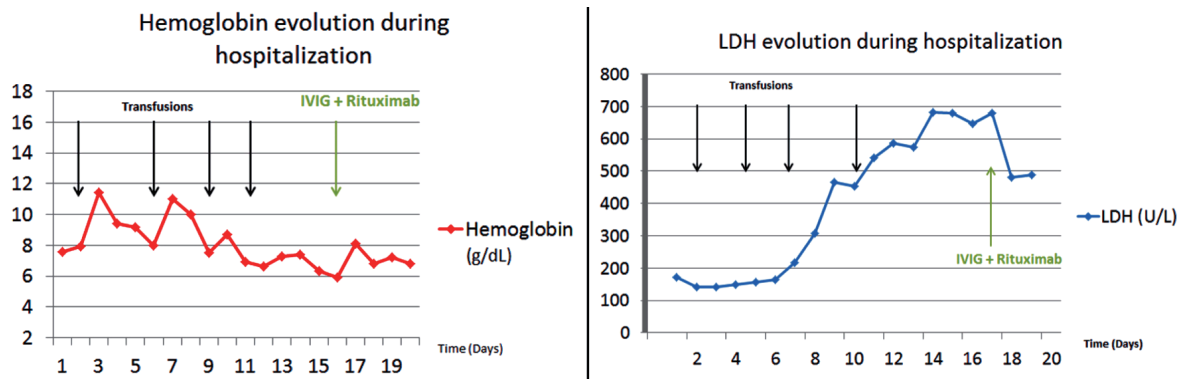


Figure 1. Hemoglobin and LDH evolution during hospitalization. LDH: lactate dehydrogenase; IVIG: intravenous immunoglobulins.

a transferrin saturation of 10%. The patient received two units of cross-matched packed RBCs on day 1 of admission. The patient was transfused again five units total on day 2 and day 5 for recurrent bleeding and an emergent colonoscopy showed diverticulosis.

She was treated with a right colectomy for uncontrolled bleeding and hemodynamic instability on day 4 of her hospitalization. Seven days after the first transfusion, the patient presented with jaundice and a drop of the hemoglobin level to 6.9 g/dL. Hemolytic anemia was diagnosed as haptoglobin levels became undetectable, LDH and total bilirubin rose to 467 U/L (normal range: 135 - 214) and 9.5 mg/dL, respectively. The patient did not show any clinical sign of bleeding. Angiography and abdominal computed tomography ruled out any recurrence of bleeding. Since her hemoglobin dropped lower than the level pre-transfusion, DHTR with HS was suspected (Fig. 1).

Diagnosis

The direct antiglobulin test (DAT, Coombs test) was 4+ positive for immunoglobulin G (IgG) and C3b. Anti-C, anti-Jk^b and anti-Fy^a alloantibodies were detected. Her erythrocyte genotype (Table 1) performed after her DHTR confirmed she was Jk^b-negative and Fy^a-negative. The extended blood phenotype of two of the units transfused was C+ c+ K- and C- c+ K+ k+, explaining the incompatibility reaction and suggesting the hemoglobin drop was not due to active bleeding.

Treatment

The patient was treated on day 17 with intravenous immunoglobulins (IVIG) 0.5 g/kg/day for 4 days and injection of epoetin alfa 40,000 IU. She also received anti-CD20 monoclonal antibody rituximab 1 g as alloimmunization prophylaxis for potential further transfusions.

Follow-up and outcomes

At day 18, her hemoglobin level stabilized and LDH started to

drop. The patient did not show any recurrence of bleeding nor hemolysis, and was safely discharged from the hospital.

Discussion

DHTR is a well-known complication in transfusion medicine especially in SCD. Clinically, DHTR can range from mild symptoms to lethal multi-organ failure, but most patients present symptoms such as jaundice, hemoglobinuria, and fever.

HS is a rare and dreaded complication and needs to be better recognized as its outcome can be fatal. The DAT is fre-

Table 1. Erythrocyte Genotype of the Patient

Screening	Result
RH2 C	Negative
RH3 E	Positive
RH4 c	Positive
RH5 e	Positive
KEL1 K	Negative
KEL2 k	Positive
KEL3 Kpa	Negative
KEL4 Kpb	Positive
KEL6 Jsa	Negative
KEL7 Jsb	Positive
FY1 Fya	Negative
FY2 Fyb	Positive
JK1 Jka	Positive
FY2 Fyb	Positive
JK1 Jka	Positive
JK2 Jkb	Negative
MNS1 M	Positive
MNS2 N	Positive
MNS3 S	Positive
MNS4 s	Positive

quently negative and reticulocytopenia is often observed [6]. As it remains exceptional, its precise incidence and mortality is not clear and most of the data concern SCD patients.

However, both DHTR and HS have been reported in patients with other underlying hematologic disorders such as thalassemia [7], myelofibrosis [8], anemia of chronic disease [9] and lymphoma [10], possibly as they also need multiple transfusions in the setting of the disease itself or the treatment-induced cytopenias. For example, a patient with non-Hodgkin lymphoma developed a DHTR with the same alloantibody, anti-Jk^b, as our patient did, and was successfully treated with steroids and extended matched Jk^b-negative transfusions [10].

Furthermore, HS is exceptional outside any hematologic condition. To the best of our knowledge, our case is one of the few described in the literature with HS in a person without any hematologic disorder [11-14].

In HS, the hemoglobin drop below pre-transfusion levels reflects the destruction of both autologous and transfused RBCs. This phenomenon is called "bystander hemolysis", as the autologous RBCs are destroyed even if they do not present the targeted antigen [6]. The exact mechanism of HS is still poorly understood, but different hypotheses have been suggested, including macrophage activation, suppression of erythropoiesis and complement activation [15].

Alloantibody identification is important for the diagnosis of DHTR and HS. In addition to anti-Jk^b, our patient developed also anti-C and anti-Fy^a alloantibodies which are classically known to be harmful alloantibodies and comforted the alloimmunization suspicion.

Nevertheless, identifying the responsible antibody remains a challenge because of their transient nature. Indeed, due to antibody evanescence, one-thirds of DHTR cases will not have any identified antibody, putting at risk patients for other hemolysis reactions, acute or delayed, if transfusion is again needed [16]. In a study on 124 SCD patients, the most frequent antibodies identified were Rh antibodies (anti-D, anti-C, anti-E, and anti-e) [2]. Anti-Jk^b was less frequent than anti-Jk^a in a study in India on 405 alloantibodies; and in 32% of cases, multiple alloantibodies were involved [17].

Alloimmunization should always be kept in mind in front of an unexplained post-transfusion hemolysis, even in patients without transfusion history. Indeed, in addition to our patient case description, few cases have been reported in the literature. A patient without previous transfusions suffered from a fatal DHTR due to Kell alloantibodies thought to be related to a medical history of 13 pregnancies [11]. An previous report of a 58-year-old patient from Haiti who had never been transfused in the past but was known with a history of five pregnancies and two abortions, presented with a severe DHTR due to anti-U alloimmunization after being transfused for rectal bleeding [18]; reminding that transfusions are not the only way to get alloimmunized, and obstetric history needs to be thorough.

Massive transfusions in hemorrhagic shocks are also a potential alloimmunization risk. Similar to our patient who was acutely transfused for uncontrolled gastrointestinal bleeding, a young multi-transfused patient known with prehepatic portal hypertension and bleeding varices, presented a HS successfully treated with corticosteroids and immunoglobulins [14]. Also in the context of massive transfusions, Eberly et al reported the

case of a 55-year-old patient transfused 10 units of RBCs after a motor vehicle accident who presented DHTR/HS with Jk^a alloantibodies and was not known for a hematologic disease [13]. Finally, intravenous drug abuse can be another potential cause for alloimmunization as Lappen et al showed in their study on pregnant women [19].

Given the complexity and rarity of HS, management should always be decided after discussion with the hematologist and transfusion medicine specialist. Avoidance of further transfusions is of major importance unless the patient has life-threatening anemia. First-line treatment after avoidance of transfusions is IVIG for 3 to 5 days and high-dose corticosteroids as recommended by the 2020 guidelines of the American Hematology Society [20]. High-dose erythropoietin should be given if reticulocytopenia is present and supportive care with intravenous iron should also be considered. In severe HS with organ damage, eculizumab, an anti-C5 monoclonal antibody, can be administered given that complement activation is suspected to contribute to HS although the outcome is variable [16, 21].

Recently, a life-threatening HS in a SCD patient has been successfully treated with tocilizumab, an anti-interleukin (IL)6 monoclonal antibody, suggesting macrophage activation might play a role in its mechanism and could be a potential therapeutic target [17].

These patients need extended-matching RBCs and to be monitored closely after transfusions. In SCD patients, HbA repeated dosage should be followed to exclude transfused RBCs hemolysis and the use of a diagnostic nomogram can be a helpful tool in the process [18]. A systematic antibody screening post transfusion and a thorough transfusion and alloimmunization history need to be kept in patient's medical files to bring awareness to this dangerous condition, and a nationwide antibody database could help prevent this complication [22]. Genotyping blood group antigen should be done when possible as it allows genotype-compatible transfusions in the future [5]. If transfusion is deemed necessary, an extended-matching of RBC needs to be done to identify new alloantibodies (C/c, E/e, K, Jk^a/Jk^b, S/s, M/N, Fy^a/Fy^b) [20]. Prophylaxis with steroids and/or rituximab prior to the transfusion can lower the risk of additional alloimmunization and delayed reaction in high-risk patients who might need future transfusions [20, 21].

Learning points

Still underestimated even within the SCD population, HS is a potentially life-threatening condition which can also affect individuals without an underlying hematologic condition. Despite all matching safety measures, DHTR and HS need to be suspected by clinicians even in non-SCD patients, as a prompt recognition will stop additional transfusions worsening the hemolysis and allow for adequate treatment.

Acknowledgments

None to declare.

Financial Disclosure

The authors did not receive any financial support for the manuscript.

Conflict of Interest

The authors deny any conflict of interest.

Informed Consent

Verbal informed consent was obtained from the patient.

Author Contributions

KE did the literacy search. KE, FSB and MC all contributed equally to the writing of the manuscript and to the figures.

Data Availability

The data supporting the findings of this study are available from the corresponding author upon reasonable request.

Abbreviations

DHTR: delayed hemolytic transfusion reaction; DAT: direct antiglobulin test; HS: hyperhemolysis syndrome; LDH: lactate dehydrogenase; RBC: red blood cell; SCD: sickle cell disease

References

- Coleman S, Westhoff CM, Friedman DF, Chou ST. Alloimmunization in patients with sickle cell disease and under-recognition of accompanying delayed hemolytic transfusion reactions. *Transfusion*. 2019;59(7):2282-2291.
- Habibi A, Mekontso-Dessap A, Guillaud C, Michel M, Razazi K, Khellaf M, Chami B, et al. Delayed hemolytic transfusion reaction in adult sickle-cell disease: presentations, outcomes, and treatments of 99 referral center episodes. *Am J Hematol*. 2016;91(10):989-994.
- Vichinsky EP, Earles A, Johnson RA, Hoag MS, Williams A, Lubin B. Alloimmunization in sickle cell anemia and transfusion of racially unmatched blood. *N Engl J Med*. 1990;322(23):1617-1621.
- Banks M, Shikle J. Hyperhemolysis syndrome in patients with sickle cell disease. *Arch Pathol Lab Med*. 2018;142(11):1425-1427.
- Narbey D, Habibi A, Chadebech P, Mekontso-Dessap A, Khellaf M, Lelievre JD, Godeau B, et al. Incidence and predictive score for delayed hemolytic transfusion reaction in adult patients with sickle cell disease. *Am J Hematol*. 2017;92(12):1340-1348.
- Treleaven JG, Win N. Hyperhaemolysis syndrome in a patient with myelofibrosis. *Hematology*. 2004;9(2):147-149.
- Hussain SS, Ebbs AM, Curtin NJ, Keidan AJ. Delayed haemolytic transfusion reaction due to anti-Jkb in a patient with non-Hodgkin's lymphoma-transient nature of anti-Jkb and the importance of early serological diagnosis. *Transfus Med*. 2007;17(3):197-199.
- Merrill SA, Brodsky RA, Lanzkron SM, Naik R. A case-control analysis of hyperhemolysis syndrome in adults and laboratory correlates of complement involvement. *Transfusion*. 2019;59(10):3129-3139.
- Fasano RM, Miller MJ, Chonat S, Stowell SR. Clinical presentation of delayed hemolytic transfusion reactions and hyperhemolysis in sickle cell disease. *Transfus Clin Biol*. 2019;26(2):94-98.
- Makroo RN, Nayak S, Chowdhry M, Karna P. Facts and fallacies of kidd antibodies: experience in a tertiary care hospital in North India. *Indian J Hematol Blood Transfus*. 2017;33(2):254-258.
- Taliano V, Fleury M, Pichette R, Lamothe M, Decary F. [Delayed hemolytic transfusion reaction caused by an anti-U]. *Rev Fr Transfus Hemobiol*. 1989;32(1):17-26.
- Chubar E, Bisharat N. Fatal delayed haemolytic transfusion reaction in a patient without previous transfusions but with an obstetric history of 13 pregnancies. *BMJ Case Rep*. 2017;2017:bcr-2017-222343.
- Eberly LA, Osman D, Collins NP. Hyperhemolysis Syndrome without Underlying Hematologic Disease. *Case Rep Hematol*. 2015;2015:180526.
- Chou ST, Alsawas M, Fasano RM, Field JJ, Hendrickson JE, Howard J, Kameka M, et al. American Society of Hematology 2020 guidelines for sickle cell disease: transfusion support. *Blood Adv*. 2020;4(2):327-355.
- Gupta S, Fenves A, Nance ST, Sykes DB, Dzik WS. Hyperhemolysis syndrome in a patient without a hemoglobinopathy, unresponsive to treatment with eculizumab. *Transfusion*. 2015;55(3):623-628.
- Dumas G, Habibi A, Onimus T, Merle JC, Razazi K, Mekontso Dessap A, Galacteros F, et al. Eculizumab salvage therapy for delayed hemolysis transfusion reaction in sickle cell disease patients. *Blood*. 2016;127(8):1062-1064.
- Lee LE, Beeler BW, Graham BC, Cap AP, Win N, Chen F. Posttransfusion hyperhemolysis is arrested by targeting macrophage activation with novel use of Tocilizumab. *Transfusion*. 2020;60(1):30-35.
- Mekontso Dessap A, Pirenne F, Razazi K, Moutereau S, Abid S, Brun-Buisson C, Maitre B, et al. A diagnostic nomogram for delayed hemolytic transfusion reaction in sickle cell disease. *Am J Hematol*. 2016;91(12):1181-1184.
- Lappen JR, Stark S, Gibson KS, Prasad M, Bailit JL. Intravenous drug use is associated with alloimmunization in pregnancy. *Am J Obstet Gynecol*. 2016;215(3):344 e341-346.
- Pirenne F, Yazdanbakhsh K. How I safely transfuse patients with sickle-cell disease and manage delayed hemo-

- lytic transfusion reactions. *Blood*. 2018;131(25):2773-2781.
21. Noizat-Pirenne F, Bachir D, Chadebech P, Michel M, Plonquet A, Lecron JC, Galacteros F, et al. Rituximab for prevention of delayed hemolytic transfusion reaction in sickle cell disease. *Haematologica*. 2007;92(12):e132-135.
22. Powell Z, Jiang N, Shrestha R, Jackson DE. Would a National Antibody Register contribute to improving patient outcomes? *Blood Transfus*. 2021;20(2):132-142.